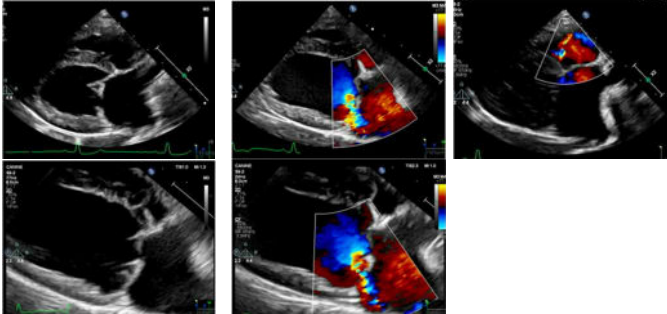
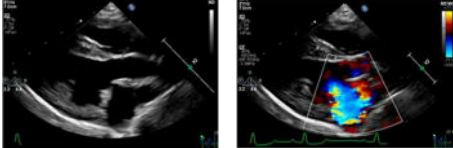
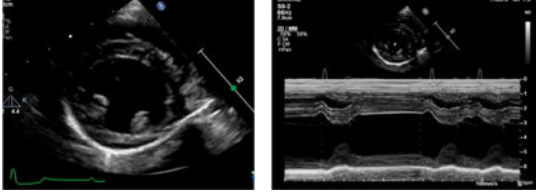
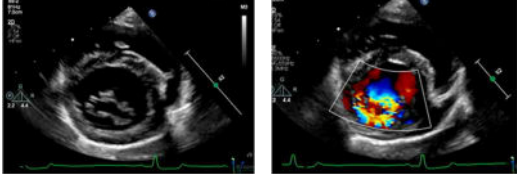
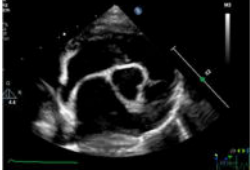
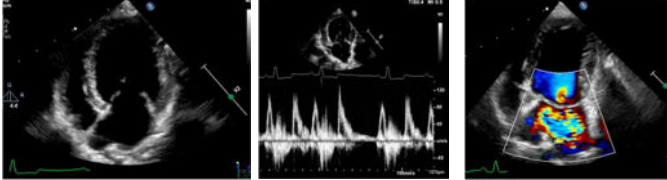


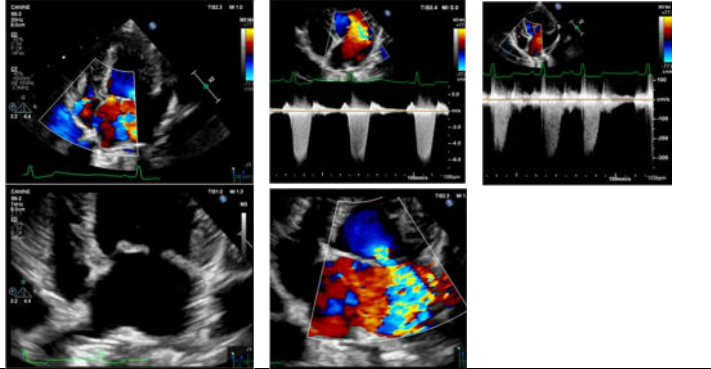
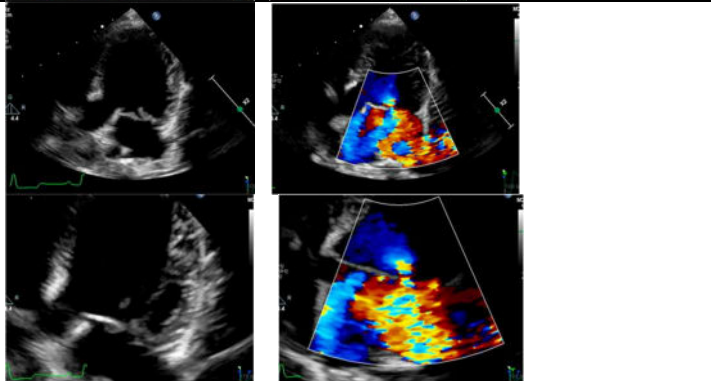
Pre-operative Evaluation For Transapical Edge-to-edge Mitral Valve

- *Echocardiographic images to acquire:*

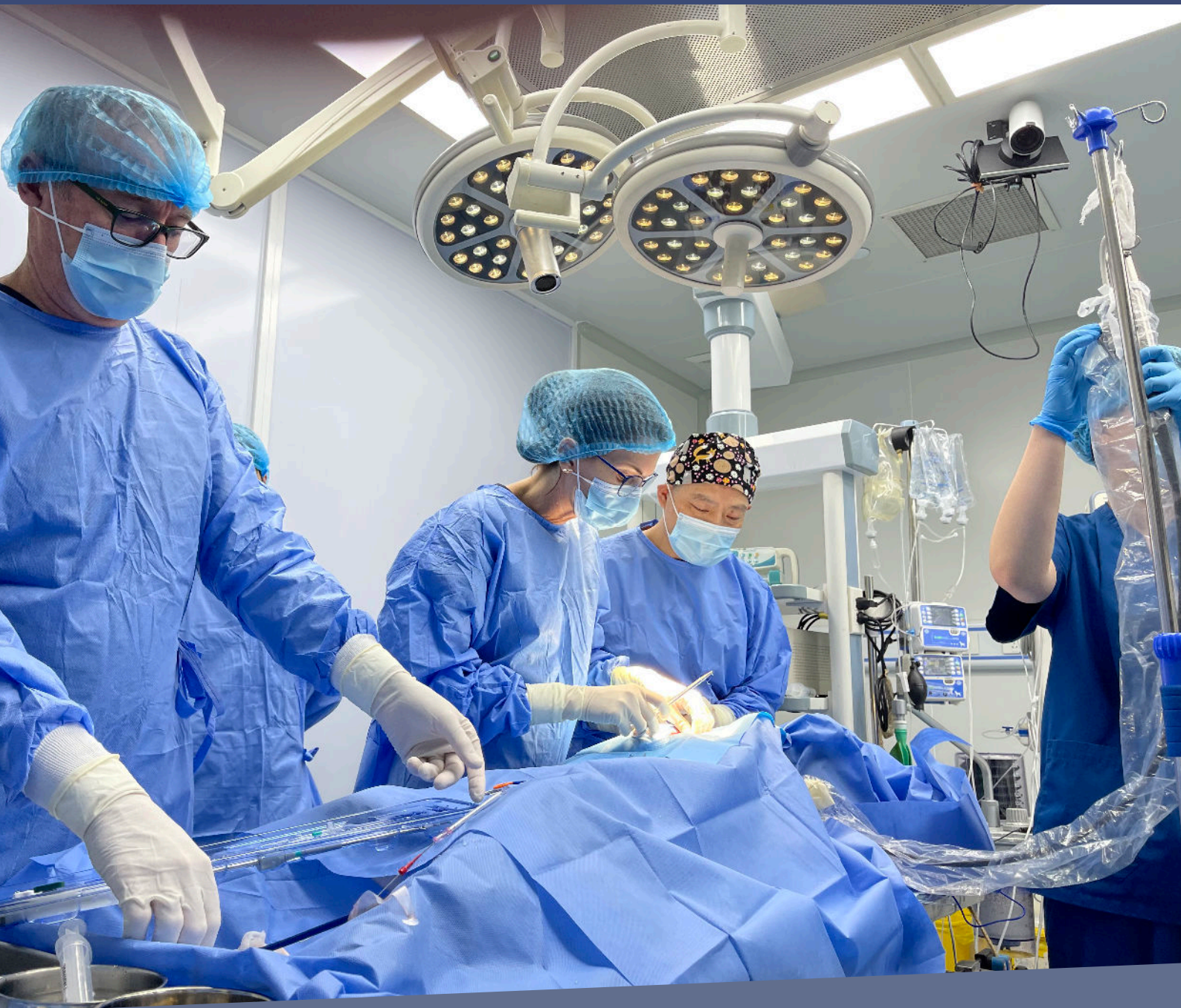<p>Right parasternal long-axis 4-chamber view</p> <ul style="list-style-type: none"> • 2D (optimized for LA and LV) • Color Doppler on MV (include entire LA) and TV • Zoomed image of MV <ul style="list-style-type: none"> ○ 2D ○ Color Doppler on zoomed image 	
<p>Right parasternal long-axis inflow-outflow view</p> <ul style="list-style-type: none"> • 2D • Color Doppler on MV 	
<p>Right parasternal short-axis (LV at level of papillary muscles)</p> <ul style="list-style-type: none"> • 2D • LV M-mode 	
<p>Right parasternal short-axis (LV at level of mitral valve)</p> <ul style="list-style-type: none"> • 2D • Color Doppler 	
<p>Right parasternal short-axis (heart base – aorta and LA)</p> <ul style="list-style-type: none"> • 2D 	
<p>Left parasternal apical four-chamber view</p> <ul style="list-style-type: none"> • 2D • MV inflow velocities – PW Doppler • Color Doppler on MV and TV <ul style="list-style-type: none"> ○ MR CW Doppler ○ TR CW Doppler • Zoomed image of MV <ul style="list-style-type: none"> ○ 2D 	

Updated 4-28-2021

Pre-operative Evaluation For Transapical Edge-to-edge Mitral Valve

<ul style="list-style-type: none">○ Color Doppler on zoomed image	
<p>Left parasternal apical five-chamber view</p> <ul style="list-style-type: none">• 2D• Color Doppler on MV (include entire LA)• Zoomed image of valve<ul style="list-style-type: none">○ 2D○ Color Doppler on zoomed image	

- *Please also include list of current medications & systemic blood pressure measurement*



Contact Us

Underwood
Consulting at
Veterinary Specialist Services

The Centre @ Springwood
1-15 Lexington Rd
Underwood QLD 4119
vss@vss.net.au
(07) 3841 7011

Carrara
Consulting at
Veterinary Specialist Services

104 Eastlake St
Carrara QLD 4211
vssgoldcoast@vss.net.au
(07) 5530 6370